

# REVIEW ARTICLE

---

## LIPOMA RARE PRESENTATIONS.

Mohan.S. V.S, B. V. Sushil Kumar

1. Assistant Professor. Department of Surgery, Shimoga Institute of Medical Sciences, Shimoga
2. Professor & HOD. Department of Surgery, Shimoga Institute of Medical Sciences, Shimoga

### CORRESPONDING AUTHOR:

Dr. Mohan.S.V.S,  
"Sapthagiri" A.N.K Road,  
1<sup>st</sup> Cross, Achuthrao Layout,  
Shimoga- 577201, Karnataka.  
E-mail: sv.s.mohan@yahoo.com  
Ph: 0091 9844097444.

**KEYWORDS:** Lipoma, Dercum's disease, Neurolipoma, Pseudolipoma, Retrobulbar lipoma

**ABSTRACT:** The ordinary lipoma is the most common benign tumor of mesenchymal origin. Only 10 to 13% of them are in Head and Neck region (as reported earlier). Rarely they can develop in the anterior and posterior aspect of neck, infratemporal fascia, palmar aspect of hand, eyelids, forehead over mandibular region and parotid gland. The diffuse variety and pedunculated lipomas are also rare. Differential diagnosis of these rare forms of lipomas are made, however CT allows a specific diagnosis to be made in all cases of rare locations of Lipomas.

**INTRODUCTION:** Lipoma (Non-cancerous) is a benign tumor arises from fat cells of adult type or mature fat cells. The typical lipoma is soft, rubbery lump located just beneath the skin. They are slow growing and usually painless, being subcutaneous swelling it is freely mobile. Lipoma could be single, multiple and rarely unencapsulated and sometimes painful (neuro lipomas –eg- Dercum's disease).

They are most often found on the upper back, shoulders, arm, buttocks and upper thigh. Less commonly these tumors are found in deeper tissues of the thigh, shoulder, head and neck, palmar aspect of palms, plantar aspect of foot, calf region, eyelids and brain.

Although lipoma can occur at any age, they most often appear between the age of 40-60 years. They are the most common soft tissue tumors found in adults. They occur more often in males than in females. Lipomas usually do not often change their form and have very little potential for malignancy.

**METHODS:** Records of all the individuals operated for lipoma during the period of Jan-2012 to Dec-2012 reviewed retrospectively. Data were collected for location, presentation, age, sex, treatment and outcome. The basic investigations were done for all the patients. Additional investigations were carried out according to their site and associated findings. The excisions of lipoma is done and sent for histopathological examination.

**RESULTS:** During the period of Jan-2012 to Dec-2012, 46 cases (21 males and 25 females) were diagnosed to have lipoma. In this study period females were more encountered with lipomas when compare to males. Out of 46 cases, two cases found to be child of age below 20 years and rest from 20-70 years of age. Among 46 cases, the back was the most commonest site (17 cases),

# REVIEW ARTICLE

forearm and thigh(11 cases), nape of neck(2 cases), anterior abdominal wall(4 cases), gluteal and axilla(2 cases).

The rare presentations of 10 lipoma encountered were given in the table

Sl.No	Age	Sex	Presentation	D/D
1	32	Male	Pseudolipoma of lateral aspect of forearm	
2	38	Female	Pseudolipoma of back	
3	44	Female	Pseudolipoma of back	
4	37	Male	Palmar aspect of the hand	Implantation dermoid Tenosynovitis
5	11	Male	The mandibular region of the chin	sebaceous cyst Neurofibroma
6	7	Male	Retrobulbar Lipoma	Vascular tumour, Mixed tumour of hydatid, inflammatory cyst and lacrimal gland.
7	60	Female	lipoma of forehead	Sequestration dermoid
8	50	Male	Pedunculated lipoma of back	Papilloma
9	44	Male	Pedunculated lipoma of elbow	Papilloma
10	45	Male	Huge Lipoma over posterior aspect of the neck(history wise present since childhood)	Congenital lymph cyst.

**DISCUSSION:** Lipoma also known as universal tumor as it can occur anywhere in the body but for exceptions like choroid of eye and brain.

In a retrospective study of lipomas was done of 46 patients regarding age, sex, site of appearance in our hospital (Shimoga Institute of Medical Sciences, Shimoga) from Jan-2012 to Dec-2012, out of 46 cases of lipoma, 2 cases was found to be aged below 20 years and rest from 20-70 years of age.

Female sex was predominantly more to have lipomas. Apart from usual presentation of lipoma like back, thighs, nape of the neck, anterior abdominal wall some of rare presentation encountered and they are 10 out of 46 cases.

3 cases of pseudolipomas were encountered (2 in back and 1 in lateral forearm) which is a rare variety of diffuse type or pseudolipoma.

The diffuse lipoma is rare inherited disorder in which there is a great local increase of subcutaneous fat without any distinct boundary or capsule. This fat is not available for metabolic use, even in starvation. These growths are generally symmetrical and are most common over mastoid process, nape of neck and in submaxillary region.

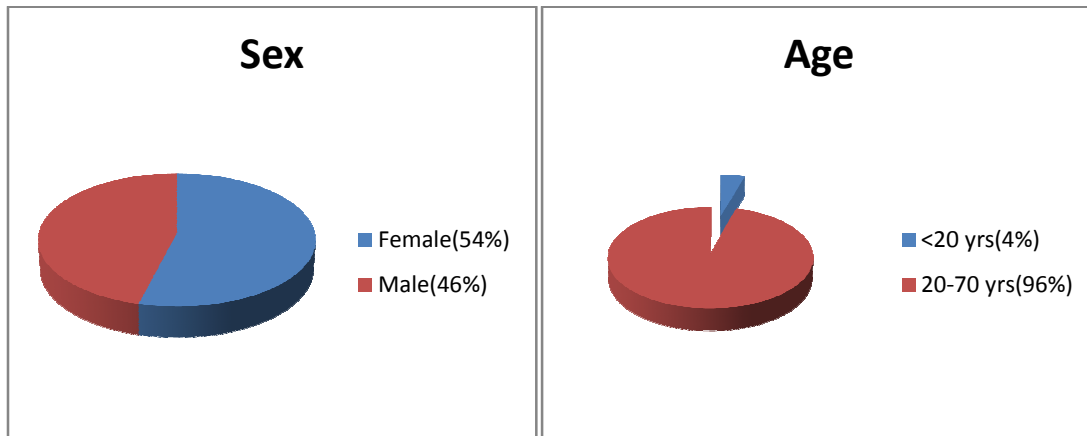
**CONCLUSION:** Rare presentation of benign lipoma may be a difficult task for the surgeons to diagnose and to come to a proper conclusion about treatment. Lipomas should be considered in the D/D of masses even in rare locations.

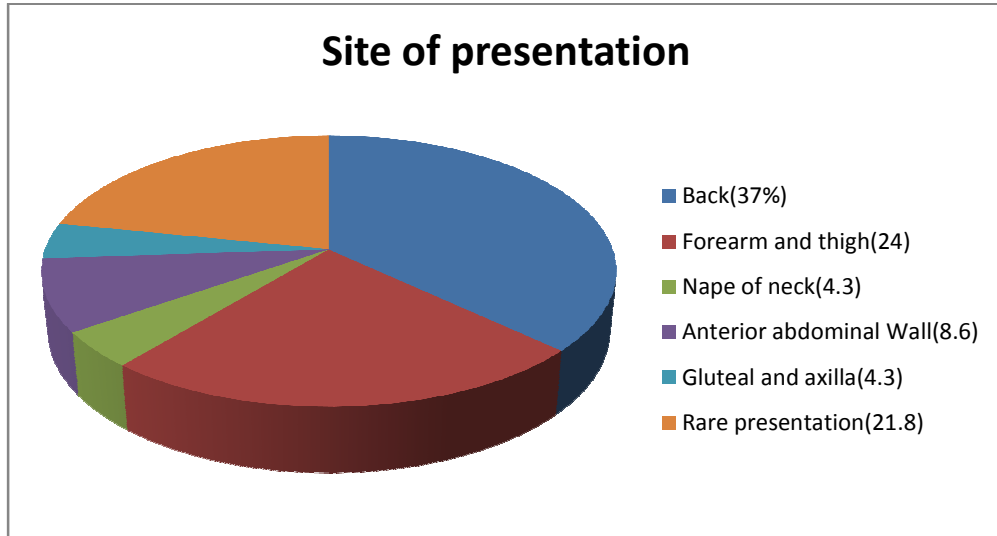
## REVIEW ARTICLE

However because of advent of invasive investigations, procedures like CT scan has helped the surgeon to come to diagnosis. Capsulated or true lipomas are easy to diagnose when compared to pseudolipoma. Surgery of capsulated lipoma is easy compare to diffuse variety.

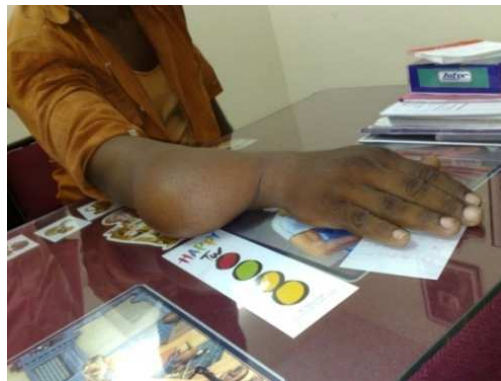### REFERENCES:

1. Bancroft LW, Kransdorf MJ, Peterson JJ, O'Connor MI (October 2006). "Benign fatty tumors: classification, clinical course, imaging appearance, and treatment". *Skeletal Radiol.* 35 (10): 719-33.
2. Weiss SW, Goldblum JR. Benign Lipomatous Tumors. In: Enzinger FM, Weiss SW, eds. *Soft Tissue Tumors*. 3rd ed. St Louis, Mo: Mosby; 1995:381-430.
3. Phalen GS, Kendrick JI, Rodriguez JM. Lipomas of the upper extremity: a series of fifteen tumors in the hand and wrist and six tumors causing nerve compression. *Am J Surg.* 1971;121(3):298-306.
4. Rydholm A, Berg NO. Size, site and clinical incidence of lipoma: factors in the differential diagnosis of lipoma and sarcoma. *Acta Orthop Scand.* 1983;54(6):929-34.
5. Hoehn JG, Farber HF. Massive lipoma of the palm. *Ann Plast Surg.* 1983;11(5):431-3.
6. Dalal KM, Antonescu CR, Singer S. Diagnosis and management of lipomatous tumors. *J Surg Oncol.* 15 2008;97(4):298-313
7. Cribb GL, Cool WP, Ford DJ, Mangham DC. Giant lipomatous tumours of the hand and forearm. *J Hand Surg Br.* 2005;30(5):509-12.
8. Bancroft LW, Kransdorf MJ, Peterson JJ, O'Connor MI. Benign fatty tumors: classification, clinical course, imaging appearance, and treatment. *Skeletal Radiol.* 2006;35(10):719-33.





This pseudolipoma is one of the clinical types of lipoma where classical signs like “Slip sign” cannot be elicited, borders are not well made out, mobility cannot be made easily, soft to firm in consistency and non tender. Excision of the tumor is done after confirming the diagnosis and sent for histopathological examination.



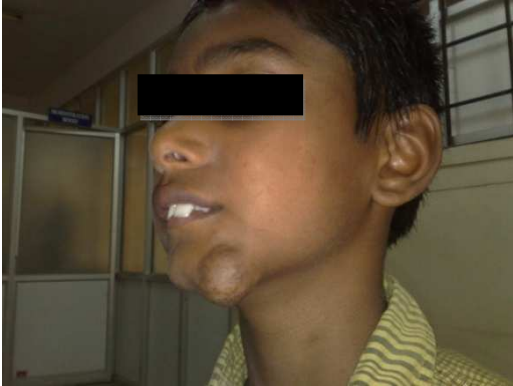1 case of lipoma found over the palmar aspect of the hand in a male patient is of a rare variety. Borders are not well made out, lobulations couldn't be appreciated, diagnosis confirmed by FNAC and excision done.



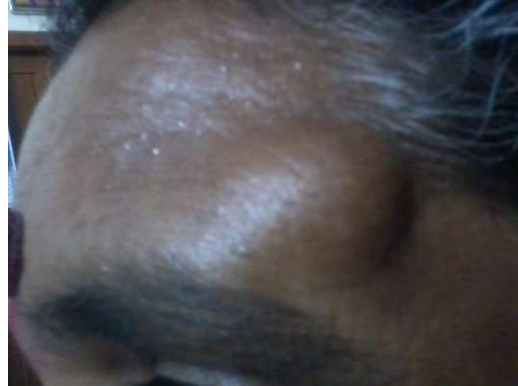## REVIEW ARTICLE

---

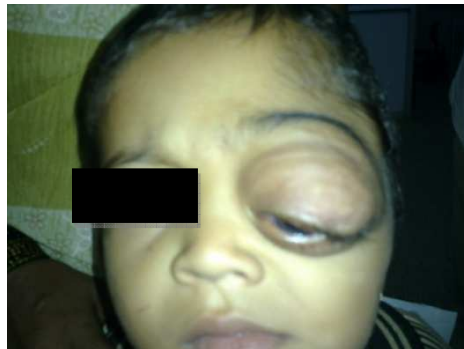Lipoma encountered over the mandibular region of the chin. X-ray of the part taken and s/o involvement of the underlying bone, i.e. Mandible. D/D made as sebaceous cyst and neurofibroma.



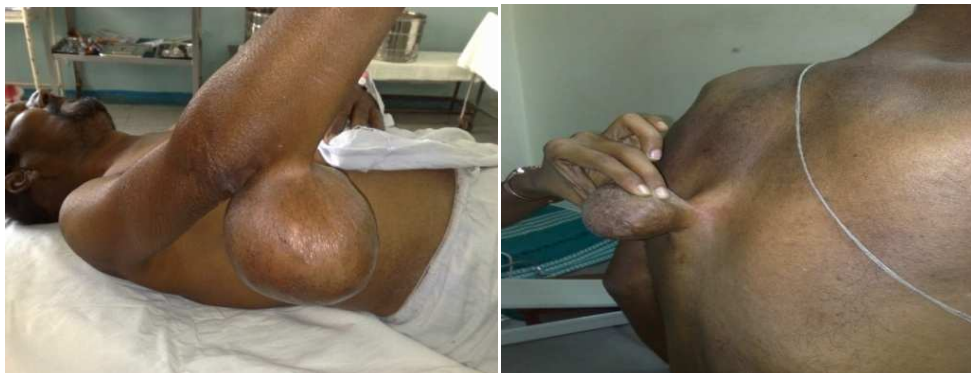Dermoid was ruled out in a case of lipoma of forehead in the embryonic fusion line by taking a X-ray of skull and not palpating indentation of bone.



Retrobulbar Lipoma- Lipomas are rare that resembles a variety of other orbital masses. CT scan revealed a well circumscribed lesion.



Pedunculated lipoma found over the back and elbow region which grew slowly in years. One of the D/D made was papiloma which was excised.



A huge lipoma (Figure 1) encountered in the posterior aspect of the neck extending from at the level of mastoid region to the level of left clavicle is in a oblique fashion which was there since birth according to the history taken in a 45 year old male patient. Patient presented as a slow growing swelling with history of pain and restricted neck movements in recent years. There was no history of sudden increase in size of the swelling. On clinical examination, it was soft in

## REVIEW ARTICLE

---

consistency, non tender, skin over the swelling was free, mobile and no restriction of mobility after putting underlying muscle into contraction. Surface was lobulated, no dilated vessels or pulsations seen. Borders were well made out. FNAC done. CT of the region (Fig-2) taken to know the underneath extension into deeper structures of neck. After confirming there was no malignant transformation, total excision of tumor (Fig-3) done and sent for HPE which revealed as benign lipoma.

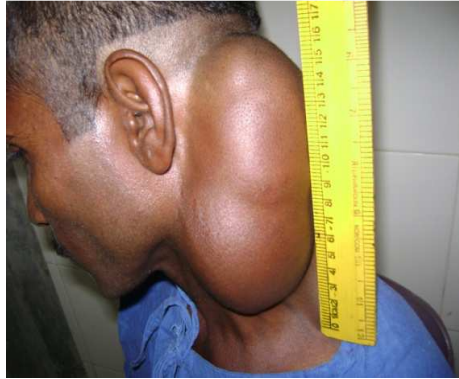

Figure 1 shows huge lipoma, left posterior aspect of the neck, presenting since childhood

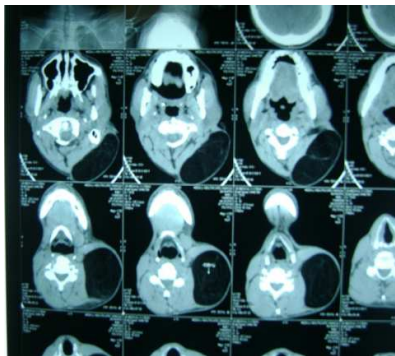


Figure 2 CT showing encapsulated mass measuring 11.3 cm superoinferiorly, 8.9 cm anteroposteriorly and 6.3cm transversely without infiltrating surrounding structure

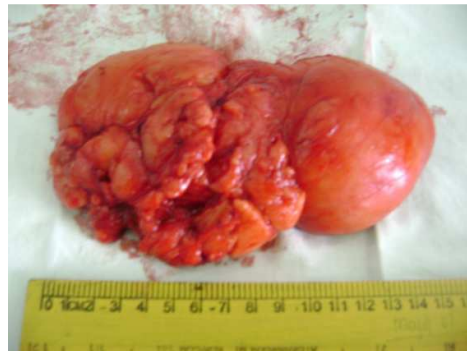

Figure 3 Excised specimen of the lipoma