

HYDATID CYST-SURGICAL MANAGEMENT

Mohan S.V.¹, T.M. Shashidhara², B.V. Susheel Kumar³

HOW TO CITE THIS ARTICLE:

Mohan S.V.S, T.M. Shashidhara, B.V. Susheel Kumar. "Hydatid cyst- surgical management". Journal of Evolution of Medical and Dental Sciences 2013; Vol2, Issue 31, August 5; Page: 5903-5908.

ABSTRACT: Hydatid cyst of the liver is rampant in developing country like INDIA. Owing to lack of awareness, patient is often present with few complications which is frustrating. However early diagnosis and management of hydatid cyst give a good clinical outcome. **METHODS:** In this study 10 patients with hydatid cyst of liver were collected over a period of 2 year interval attending SIMS Shimoga. **RESULTS:** Out of 10 cases, 2 cases are treated with Tab. Albendazole 400 mg bid over a period of 4 months with 21 days cycle and recovered well without any surgical intervention. Rest of the cases recovered well without any recurrence till date following surgery. Surgery combined with medical treatment by Tab Albendazole is effective in control of hepatic hydatid cyst and also helps in prevention of local recurrence.

INTRODUCTION: Liver hydatid disease is a zoonosis caused by larva of dog tapeworm, "ECHINOCOCCUS GRANULOSUS", with man acting as an accidental intermediate host.

Liver hydatidosis is characterized by progressive growth of the hydatid cyst, which in its mature form is a fluid filled cavity, delineated by an external host derived layer called PERICYST and two internal parasite derived layers called ENDOCYST. The hydatid cyst grows slowly and remains asymptomatic for many years. Symptoms arrive only when the cyst has grown large enough to cause the pressure on adjacent organs or complications like infection occurs. [1]

MATERIALS AND METHODS: This clinical study of hydatid cyst liver is based on 10 patients admitted and treated (from Jan 2010 to Dec 2012) in SIMS McGAnn teaching hospital, Shimoga.

Totally, 10 cases of hydatid cyst of liver were encountered. The age, sex of each patient was noted. There were 7 females and 3 males. Age ranged from 15 to over 60 years.

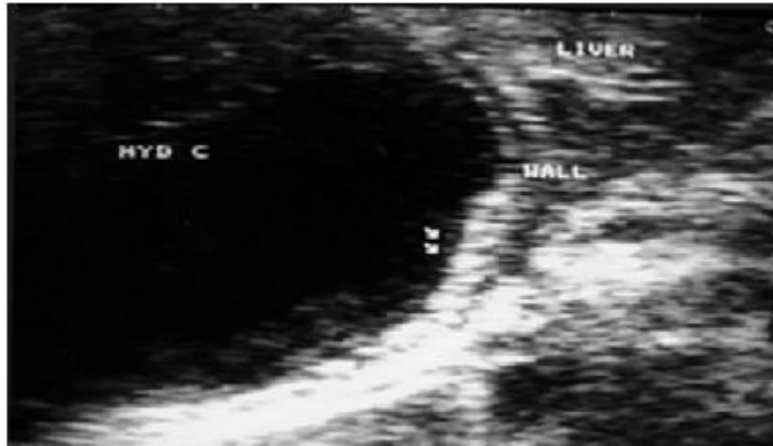

REVIEW ARTICLE: The profession and socio economic status were also noted. Majority of the patients were from rural areas and poor socio economic status and gave history of rearing cattle's'.

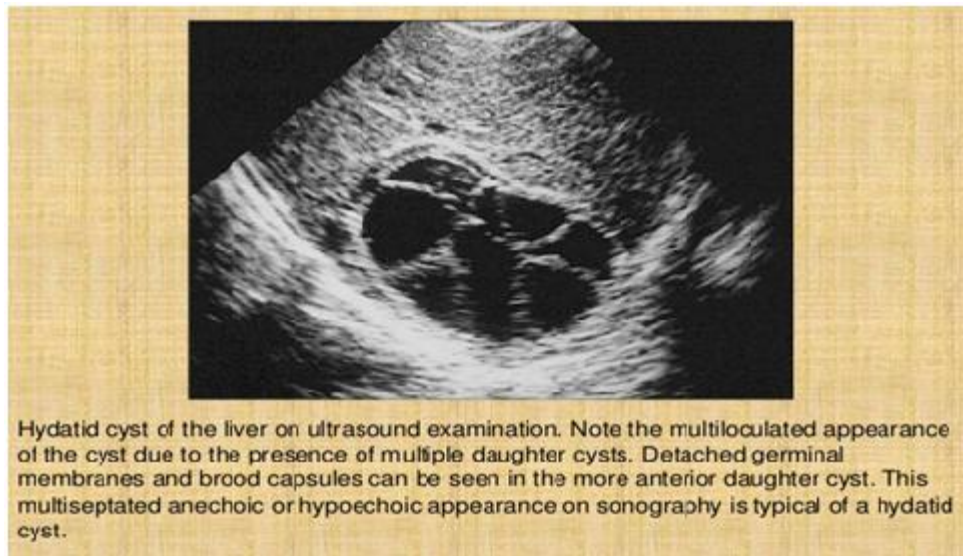
Majority of the patients presented with dragging dull aching pain in right hypochondriac or epigastric region. 2 presented with mass per abdomen where the mass was felt in right hypochondriac, epigastric region with smooth surface, rounded border which was non tender. 2 of the patients presented with features of infected hydatid cyst i.e. fever, tender mass and vomiting.

ORIGINAL ARTICLE

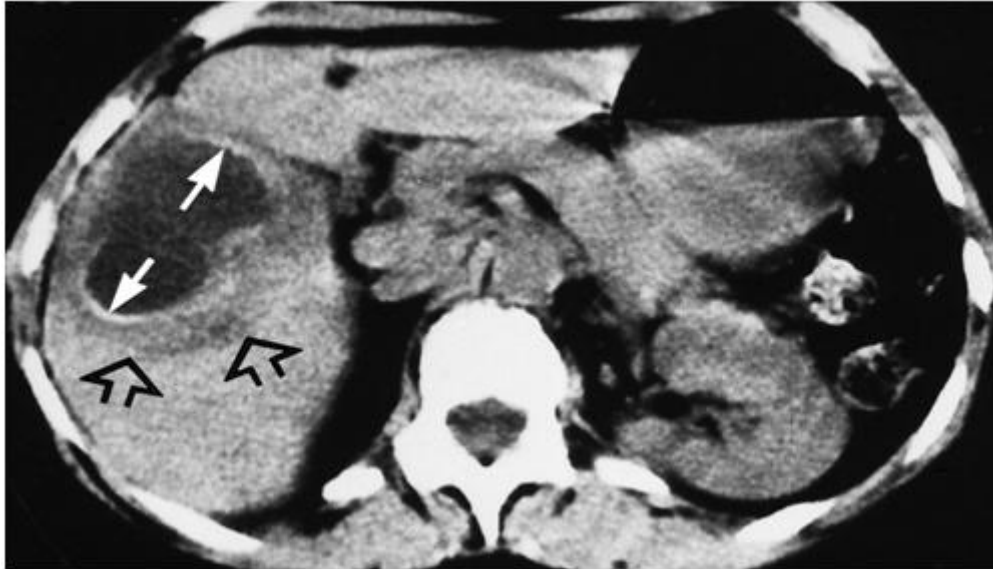
None of them in this study presented with jaundice or intraperitoneal or pulmonary complications. Apart from routine laboratory investigations, USG abdomen and CT abdomen was done to confirm the diagnosis which revealed “cart wheel appearance”. [6] None of the patient in this study showed calcification of the cyst.



USG showing hydatid cyst of liver.



Hydatid cyst of the liver on ultrasound examination. Note the multiloculated appearance of the cyst due to the presence of multiple daughter cysts. Detached germinal membranes and brood capsules can be seen in the more anterior daughter cyst. This multiseptated anechoic or hypoechoic appearance on sonography is typical of a hydatid cyst.

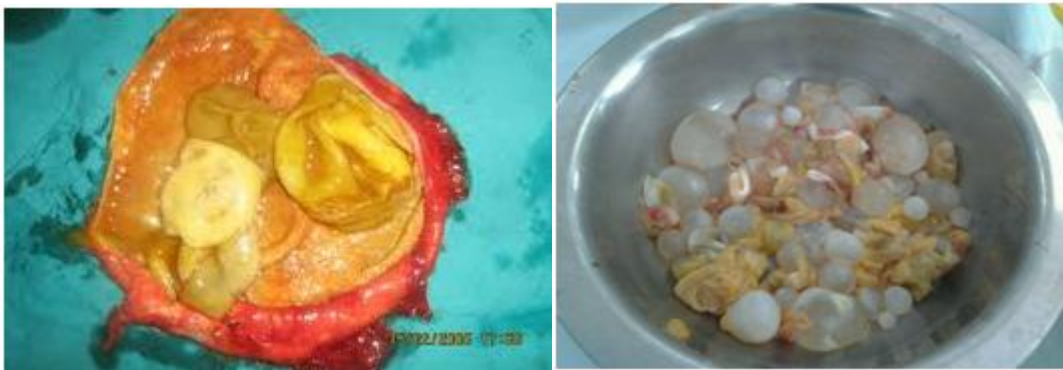

CT showing hydatid cyst liver.

Among 10 patients, 2 were treated conservatively with Tab Albendazole since the size of the cyst was less than 5-6 cms. So the trial of Tab Albendazole 400mg was given twice daily for 6 weeks.

REVIEW ARTICLE: Repeated courses of Albendazole can be tried over a period of 6 months. Care was taken to watch for neutropenia during the treatment.

Rest of the 8 patients required surgical excision of the cyst. 5 patients underwent pericystectomy and other 3 patients had to undergo cystectomy and capitonnage. During surgery care was taken to avoid spillage into peritoneal cavity by proper abdominal packing with scolicial agents to avoid peritoneal hydatid. [5]



SPECIMENS SHOWING HYDATID CYSTS OF LIVER

Tab Albendazole was started 10 mg/kg/day for 15 days preoperatively. [4] Inj. hydrocortisone 100mg was given slow I.V. before, during and after surgery to prevent anaphylactic reaction. Proper scolicial agents like 20% hypertonic saline was used to deactivate the cyst content. Prior to injection of this solution into cystic cavity, the content of the cysts were completely aspirated to prevent dilution of the agent. The solution was left inside the cyst for 10 minutes to kill

ORIGINAL ARTICLE

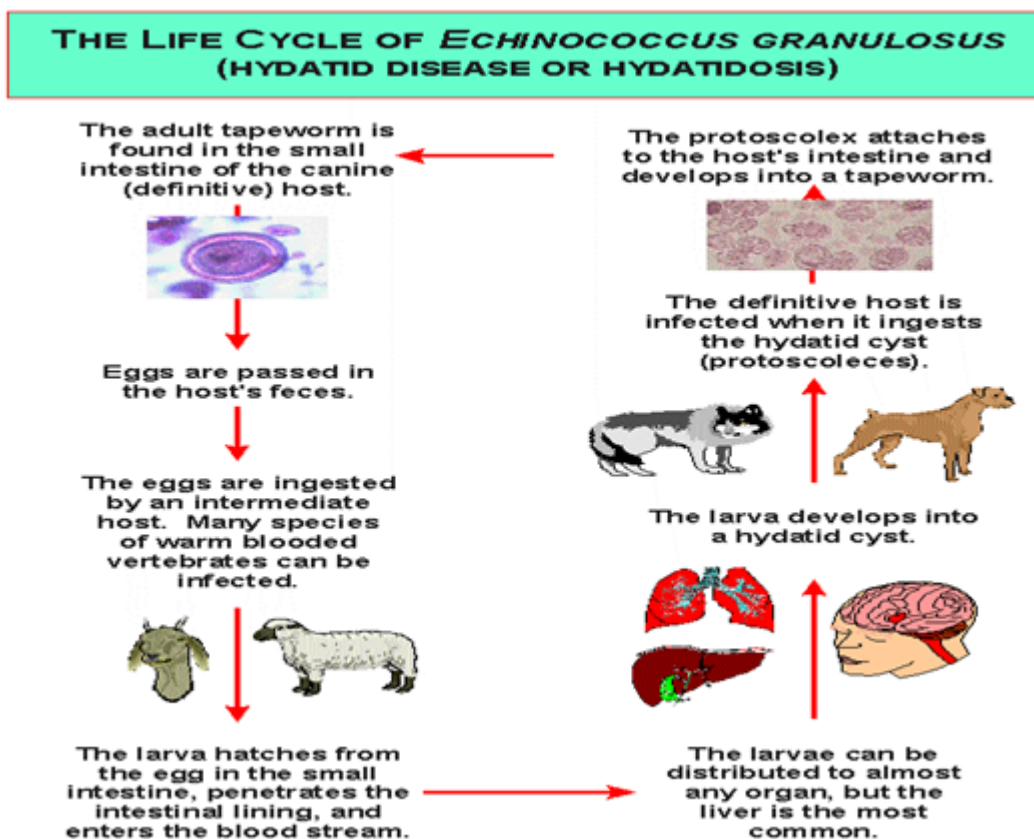
the scolices. Other scolicidal agents which can be used are formaldehyde, cetrimide solution, sodium hypochlorite solution, 80% alcohol and chlorhexidine.

Post operative complications were negligible.

DISCUSSION: Hydatid cyst is a zoonotic disease that occurs throughout the world particularly in those areas where the people are involved in cattle rearing profession. Usually two types of Echinococcus infections are seen i.e. "ECHINOCOCCUS GRANULOSUS" and "ECHINOCOCCUS MULTILOCULARIS". In human this cyst is caused by larva of a tapeworm, "ECHINOCOCCUS GRANULOSUS" whereas "ECHINOCOCCUS MULTILOCULARIS" is uncommon but more invasive mimicking a malignancy, so it is called MALIGNANT HYDATID CYST DISEASE.

The life cycle of "ECHINOCOCCUS GRANULOSUS" alternates between carnivores and herbivores for instance between dogs and sheep, whereas man is an accidental intermediate host with ending point in parasite's life cycle. [2] The liberated ova burrows through the intestinal mucosa and are carried by portal vein to the liver, where they develop into adult cysts. Liver is most common site of hydatid disease and most cysts are located in right lobe.

REVIEW ARTICLE



Some ova pass through capillary sieve and become lodged in any part of the body through the bloodstream and reaches the lung ,peritoneum, kidney, brain, mediastinum, heart, bone, soft tissues and most of the other parts of the body.

ORIGINAL ARTICLE

Sometimes hydatid cysts may be remained asymptomatic for years long. Its presence may become evident when hepatomegaly is found or a cystic lesion is noted when the liver is imaged for other factors and diseases. It may be painful or may lead to complication such as rupture into biliary tract or peritoneal cavity which may cause cholangitis, anaphylactic shock and other infections.

Hydatid cyst can be solitary or multiple in nature. Image findings depend upon the stage of cyst growths. Lab studies in most cases show normal results. The diagnosis can be confirmed with imaging modalities.

Ultrasound is currently the primary diagnostic technique and has diagnostic accuracy of 90%. [3] CT scan has the highest sensitivity of imaging of the cyst (100%) and it is the best mode to detect number, size and location of the cyst. It may provide clue to presence of complications such as infections and intra biliary or intrapulmonary rupture. CT features include sharply marginated single/multiple rounded cysts of fluid density with a thin dense rim of septations giving rise to "CART WHEEL APPEARANCE".

Medical line of treatment of hydatid cysts with drugs like Mebendazole/Albendazole has been reported to be effective if the size of the cyst is less than 5-6 cms. with a trial of drugs for 6 weeks, but medical therapy alone has a controversial result. [4] It has been used successfully in prevention of post operative local recurrence and sterilization before surgery.

Percutaneous drainage (PAIR) had been proposed as an alternative to surgery especially for the patients who don't want to undergo surgical procedure. Surgery is considered as best possible treatment having potential to remove the cyst and to give complete cure. The main principle of surgical treatment is to eradicate the parasite, prevent intra operative spillage of contents of cyst and obliterate the residual cavity. [5]

Recurrence of hydatid cyst may occur either from spillage of hydatid fluid during the surgical procedure or reinfestation.

CONCLUSION: Hydatid cyst of liver due to "ECHINOCOCCUS GRANULOSUS" infection remained a challenging clinical problem throughout the world.

USG abdomen, CT abdomen and thorax are the gold standard investigations for early diagnosis. Sometimes x-ray chest and abdomen also reveals calcified hydatid cyst.

The aim of surgical treatment should be for complete drainage and obliteration of the cyst cavity in liver without spillage.

Post operative trial of Tab Albendazole 400mg bid for a period of one month can be tried to prevent local recurrence.

REFERENCES:

1. Sayek I, Yalin R, Sanac Y. Surgical treatment of hydatid disease of the liver. Arch Surg. 1980;115:847-50
2. Harris KM, Morris DL, Tudor R, Toghil P, Hardcastle JD. Clinical and radiographic features of simple and hydatid cysts of the liver. Br J Surg. 1986; 73:835-8.
3. Gharbi HA, Hassine W, Brauner MW, Dupuch K. Ultrasound examination of the hydatid liver. Radiology. 1981;139:459-63
4. Kern P. Echinococcus granulosus infection: clinical presentation, medical treatment and outcome. Langenbecks Arch Surg. 2003;388:413-20

ORIGINAL ARTICLE

5. Dziri C, Paquet JC, Hay JM, Fingerhut A, Msika S, Zeitoun G, et al. Omentoplasty in the prevention of deep abdominal complications after surgery for hydatid disease of the liver: a multicenter, prospective, randomized trial. French Associations for Surgical Research. J Am Coll Surg. 1999;188:281
6. Sayek I, Tirnaksiz MB, Dogan R. Cystic hydatid disease: current trends in diagnosis and management. Surg Today. 2004; 34:987-96.

AUTHORS:

1. Mohan S.V.S
2. T.M. Shashidhara
3. B.V. Susheel Kumar

PARTICULARS OF CONTRIBUTORS:

1. Assistant Professor, Department of Surgery, SIMS, Shimoga.
2. Assistant Professor, Department of Surgery, SIMS, Shimoga.
3. Professor & HOD, Department of Surgery, SIMS, Shimoga.

NAME ADDRESS EMAIL ID OF THE CORRESPONDING AUTHOR:

Dr. Mohan S.V.S,
'Sapthagiri', Ank Road,
1st Cross, Achutha Rao layout,
Shimoga - 577201.
Email - sv.s.mohan@yahoo.com

Date of Submission: 23/07/2013.
Date of Peer Review: 24/07/2013.
Date of Acceptance: 01/08/2013.
Date of Publishing: 05/08/2013