

Surgical treatment of non-specific ulcers of foot

Dr. R V Arun Kumar^{1*}, Dr. Mohan SVS², Dr. Madhurya RM³

¹Assistant Professor, Department of General Surgery, Subbaiah Institute of Medical Sciences and Research Centre, Shimoga, Karnataka, India.

²Assistant professor, Department of General Surgery, Shivamogga Institute of Medical Sciences, Shimoga, Karnataka, India.

³House surgeon, Shivamogga Institute of Medical Sciences, Shimoga, Karnataka, India.

Abstract: The objective of this study is to compare between early surgical treatments of non-specific ulcers of foot versus late treatment which required devastating surgeries like amputation. Patients for this study were selected from surgical wards of Subbaiah Institute of Medical Sciences and research centre from March 2014 to March 2015 with the following inclusion and exclusion criteria. A minimum of 10 cases of randomized non-specific ulcer foot were studied after informed consent. Among 10 cases 6 were males and 4 were females. After early treatment and minimal surgical interventions like slough excision and debridement, patients were followed regularly up to 3 to 4 weeks for outcome of the disease. Patients around 40 to 50 years of age group formed the maximum number in the study. Male to female ratio was 3:2. All the 10 patients tolerated the early surgical treatment for ulcer foot very well. None of the studied patients required further surgical intervention like disarticulation or amputation. Appropriate antibiotics according to culture and sensitivity reports were given during the study period.

Keywords: culture and sensitivity, debridement, diabetic ulcer, slough excision, varicose ulcer.

I. Introduction

Non-specific ulcers of the foot were detected and treated early with minor surgical procedures like slough excision and debridement [1] and with appropriate use of I.V/oral antibiotics following culture and sensitivity report of the secretions from the ulcer, helped in preventing further complications like extensive slough and gangrene.

The common cause for non-specific ulcers in the study was preexisting uncontrolled diabetes with history of trauma to the foot which was unnoticed in majority of the cases because of underlying microangiopathy and peripheral neuritic changes [2][3] secondary to long standing diabetes. Others causes for non-specific foot ulcers were varicose ulcers over medial aspect of the leg above medial malleolus with lipodermatosclerosis [4] in 2 of the cases, which were treated conservatively with Bisgaard [5] line of management.

The above study with minimal surgical intervention like slough excision and debridement was done in Subbaiah Institute of Medical Sciences and Research Centre.

II. Materials And Methods

The present clinical study was carried out at the surgical wards of Subbaiah institute of Medical Sciences and Research Centre from Mar 2014 to March 2015. Patients underwent both minor surgical procedures like slough excision and debridement and medical line of management with appropriate antibiotics and oral hypoglycaemic agents and Insulin injections for control of diabetes – in case of Diabetic patients and complete bed rest with foot elevation and Trendelenberg exercise with Bisgaard management in varicose ulcers.

Totally 10 patients were studied in which 6 were males and 4 were females. Out of 10 patients 8 were with diabetes and 2 were with long standing long saphenous varicose veins. Following surgical intervention and conservative treatment patients were followed up to 3 to 4 weeks.

Inclusion criteria

- Both male and female patients.
- Patients of age group 40 to 50 years.
- Consent to participate in the study.
- Study included both minor surgical procedures like slough excision and debridement and conservative line of treatment.

Exclusion criteria

- Deformed foot with involvement of bones.

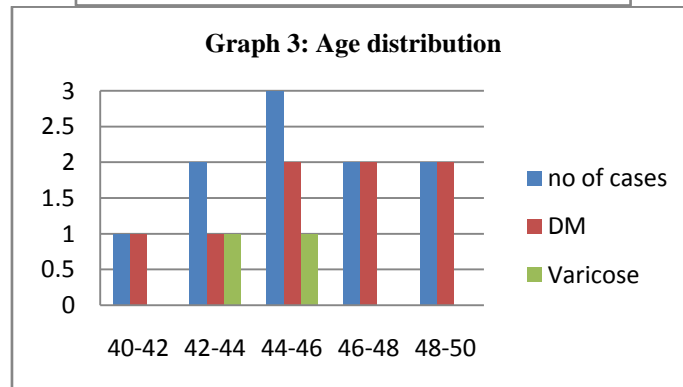
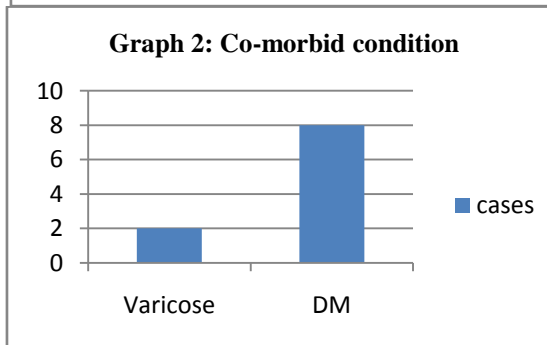
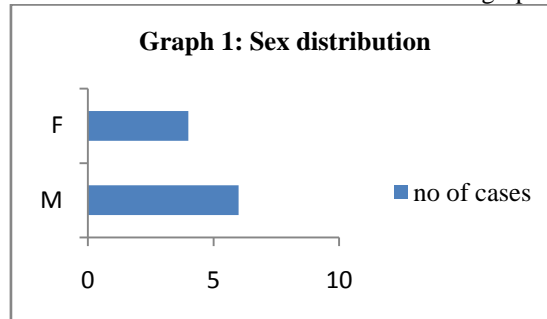
- Recurrent ulcer foot with extensive fibrosis.
- Patients with suspicion of malignancy of foot ulcers.

With support of culture and sensitivity report and use of appropriate I.V/oral antibiotics and Oral Hypoglycaemic agents or subcutaneous insulin to control diabetes, Trendelenberg exercise and crepe bandage in varicose veins and timely slough excision and debridement of slough was done and results were good.

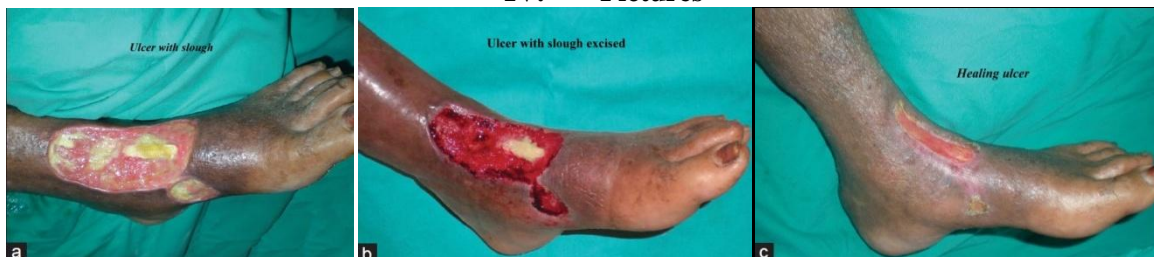III. Figures And Tables

In the 10 cases evaluated the following observations were seen;

The study shows that 60% of cases were males and 40% cases were females. It is also depicted in graph 1. In this study 2 cases of varicose ulcers and 8 cases of diabetic ulcers was seen which is depicted in graph 2. The age distribution of the cases with the co-morbid condition is shown in graph 3.



IV. Pictures



V. Inference From The Study

10 cases of non-specific foot ulcers secondary to pre-existing diabetes and long standing long saphenous varicose veins were randomly selected and treated with minor surgical procedures like slough excision and debridement and conservative management along with appropriate antibiotics and supportive treatment. The male to female ratio was 3:2(graph 2). Patients aged 40 to 43 years formed maximum number in the study (graph 1).

Use of appropriate antibiotics and supportive treatment for underlying disease with early slough excision and debridement [6] of ulcers and regular dressing with local application prevented further damage of tissues and ongoing process of the disease and its complications [7]. There was no incidence of further complications following treatment in follow-up period.

VI. Conclusion

Based on the observation made in the study, it has been concluded that early surgical intervention like slough excision and debridement with appropriate supportive treatment for underlying disease can prevent further complications and devastating surgeries like amputations [10].

References

- [1]. Steed D.L. Debridement. *The American Journal of Surgery*. May 2004 Volume 187, Issue 5 Supplement 1, Pages S71–S74; DOI: [http://dx.doi.org/10.1016/S0002-9610\(03\)00307-6](http://dx.doi.org/10.1016/S0002-9610(03)00307-6).
- [2]. Laing.P. The development and complications of diabetic foot ulcers.*The American Journal of Surgery*. Volume 176, Issue 2, Supplement 1, August 1998, Pages 11S–19S.
- [3]. McNeely.M.J, Boyko .E.J, Ahroni.J.H, Stensel.V.L, Reiber.G.E, Smith.D.G, and Pecoraro.R.E. The Independent Contributions of Diabetic Neuropathy and vasculopathy in Foot Ulceration. *DiabetesCare*.February 1995 vol. 18 no. 2 216-219 ;doi: 10.2337/diacare.18.2.216.
- [4]. Grey.J.E, Harding.K.G , Enoch.S. ABC of Wound Healing; Venous and Arterial Leg Ulcers. *BMJ*. 2006 Feb 11; 332(7537): 347–350; 2006; doi: 10.1136/bmj.332.7537.347.
- [5]. Gujja.K ,Wiley.J, Krishnan.P. Chronic Venous Insufficiency. *Interventional Cardiology Clinics*. Volume 3, Issue 4, October 2014, Pages 593–605; doi:10.1016/j.iccl.2014.07.001.
- [6]. Attinger, Christopher E, Janis, Jeffrey E, Steinberg, John D.P.M, et al. *Plastic & Reconstructive Surgery; Clinical Approach to Wounds: Débridement and Wound Bed Preparation Including the Use of Dressings and Wound-Healing Adjuvants*; June 2006 - Volume 117 - Issue 7S - pp 72S-109S doi: 10.1097/01.prs.0000225470.42514.8f.
- [7]. Edwards J, Stapley S. Debridement of diabetic foot ulcers. *Cochrane Database of Systematic Reviews* 2010, Issue 1. Art. No.: CD003556. DOI: 10.1002/14651858.CD003556.pub2.
- [8]. Curwen.I.H.M. The treatment of ulceration of the legs by physiotherapy. *The British Journal of Plastic Surgery*. Volume 6, 1953–1954, Pages 41–47.
- [9]. Andrew JM Boulton, Loretta Vileikyte, MD, Gunnel Ragnarson-Tennvall, Jan Apelqvist. The global burden of diabetic foot disease. *The Lancet*. Volume 366, Issue 9498, 12–18 November 2005, Pages 1719–1724.